

# Experience of total scapular excision for musculoskeletal tumor and reconstruction in eastern Asian countries

メタデータ	言語: eng 出版者: 公開日: 2017-11-09 キーワード (Ja): キーワード (En): 作成者: メールアドレス: 所属:
URL	<a href="https://doi.org/10.24517/00042076">https://doi.org/10.24517/00042076</a>

Experience of total scapular excision for musculoskeletal tumor and reconstruction in eastern Asian countries

Katsuhiro Hayashi<sup>a\*</sup>, Xiaohui NIU<sup>b</sup>, Xiaodong Tang<sup>c</sup>, Vivek Ajit Singh<sup>d</sup>, Apichat Asavamongkolkul<sup>e</sup>, Akira Kawai<sup>f</sup>, Norio Yamamoto<sup>a</sup>, Toshiharu Shirai<sup>a</sup>, Akihiko Takeuchi<sup>a</sup>, Hiroaki Kimura<sup>a</sup>, Shinji Miwa<sup>a</sup>, Hiroyuki Tsuchiya<sup>a</sup>

<sup>a</sup> Department of Orthopaedics, Graduate School of Medical Science, Kanazawa University, Kanazawa 920-8641, Japan

<sup>b</sup> Orthopaedic Oncology Department, Beijing JISHUITAN Hospital, Peking University Beijing 100035, China

<sup>c</sup> Musculoskeletal tumor center, People's Hospital Pecking University, Beijing 100044, China

<sup>d</sup> Department of Orthopaedic Surgery, University Malaya Medical Center, 50603 Kuala Lumpur, Malaysia

<sup>e</sup> Department of Orthopaedic Surgery, Faculty of Medicine, Siriraj Hospital, Mahidol University, 2 Prannok Road, Bangkok, 10700, Thailand

<sup>f</sup> Division of Musculoskeletal Oncology, National Cancer Center Hospital, 5-1-1 Tsukiji, Chuo-ku, Tokyo 104-0045, Japan

Correspondence to: Katsuhiro Hayashi MD, Ph.D., Department of Orthopaedic Surgery, Graduate School of Medical Science, Kanazawa University, Kanazawa 920-8641, Japan. Tel: +81 762652374, Fax: +81 762344261, e-mail: khayashi830@gmail.com

## Abstract

Total scapulectomy and reconstruction has been performed for scapular tumor, however, most of the reconstruction methods have resulted in poor functional outcomes and there is still room for improvement. Most of the reports of reconstruction after scapulectomy are from a single institution. In the present study, we investigated functional outcomes after total scapulectomy in a multicenter study in The Eastern Asian Musculoskeletal Oncology Group (EAMOG). Thirty-three patients who underwent total scapulectomy were registered at EAMOG affiliated hospitals. The patients were separated into no reconstruction group (n=8), humeral suspension group (n=15) and prosthesis group (n=10). Functional outcome was assessed by the Enneking score. One-way ANOVA was used to compare parameters between the patient groups. Complications included five local recurrences, one superficial infection, one dislocation and one clavicle protrusion. The average follow-up period was 43.5 months. The average active flexion range was 45.8° (0 – 120°), and 37.1° in abduction (0 – 120°). The mean total functional score was 22.9 out of 30 (15 - 29), which is a satisfactory score following resection of the shoulder girdle. There were significant differences in reconstruction methods for active range of motion. Bony reconstruction provided better range of motion in this study. There was a variety of reconstruction methods after scapulectomy in the eastern Asian countries. Although better functional score was obtained using scapular prosthesis or recycled bone and prosthesis composite grafting, postoperative function is still lower than preoperative function. Modified designed prosthesis with or without combination of recycle bone or allograft would restore the lost shoulder function in the future.

## Keywords

Scapulectomy; sarcoma; limb salvage surgery; megaprosthesis; recycled bone graft; functional outcome

## Introduction

Total scapulectomy has been performed for scapular tumors and has succeeded in preserving elbow and hand function. Major complications include restricted range of

motion and instability of the shoulder joint. Various reconstruction methods have been tried after scapulectomy, such as humeral suspension, prosthetic replacement, recycled bone graft, or soft tissue reconstruction. However, most of the reconstruction methods have resulted in poor functional outcomes and there is still room for improvement [1,2].

Recent reports of scapular prostheses show an acceptable range of motion and function [3,4,5,6], but there is no strong evidence of a long term positive outcome using scapular prostheses. Furthermore, a scapular prosthesis is not widely available, and the design is not well established yet.

Several problems associated with reconstruction occur after total scapulectomy. Both bone and large muscle resections are required. Each case is unique in having a different extension of the tumor and requiring a different amount of muscle sacrifice. The shoulder joint is a challenging site at which to fully restore limb function even though it is a common site for trauma involving simple fractures or rotator cuff tears. One side of the scapula is similar to a sesamoid bone [3] which is floating in soft tissue, and a prosthesis cannot be fixed in it in a manner similar to the knee or hip joints. This results in postoperative instability or malposition of the prosthesis. Recycled bone is easily absorbed postoperatively. There is also a cosmetic concern after scapulectomy such as inadequate shoulder width after simple reconstructions.

In general, most of the reports of reconstruction after scapulectomy are case series from a single institution; each hospital has its own preferred surgical procedure and reconstruction. Thus it is difficult to compare reconstruction methods from these reports. The Eastern Asian Musculoskeletal Oncology Group is a research group in the field of musculoskeletal oncology in eastern Asia. In the present study, we investigated reconstruction methods and functional outcomes after total scapulectomy in eastern Asian countries.

## Patients and methods

### Patients

This retrospective study comprised 33 patients who underwent total scapulectomy, and who were followed at least one year after surgery. Patients were registered at EAMOG affiliated hospitals. Nineteen cases were treated in China, seven in Malaysia, five in Japan, and two in Thailand. This study protocol was approved by the Institutional Review Board of the Kanazawa University Hospital, Kanazawa, Japan. This study complied with ethical standards outlined in the Declaration of Helsinki. Questionnaires

were sent to the surgeons and answers obtained voluntarily from six hospitals after institutional review-board approval. Surgeries were performed between 1993 and 2009.

### **Characteristics**

The average age of the patients was 43.1 years (15 to 75 years) (table 1). Seventeen were male and sixteen were female. Sixteen patients had chondrosarcomas, six had Ewing's sarcomas, three had osteosarcomas, two had metastatic bone tumors, two had synovial sarcomas, one had a fibrosarcoma, one had a liposarcoma, one had a malignant fibrous histiocytoma, and one had an angiosarcoma. Using Enneking's surgical stages of 31 sarcomas, three cases were classified as IB, one as IIA, 24 as IIB, and one as IIIB. Preoperative or postoperative chemotherapy was performed in 13 cases and no patients underwent irradiation.

In eight patients, neither soft tissue nor bone reconstruction was performed. In fifteen cases, soft tissue reconstruction was performed by humeral suspension. Bone defects in nine cases were reconstructed using a scapular megaprosthesis, and one was reconstructed using a recycled autologous bone and prosthesis composite. The scapular prosthesis used was a constrained reverse scapular prosthesis (ChunLi, Beijing, China). In humeral suspension group, the residual humerus was suspended from the clavicle or a proximal rib. Biceps tendon or rotator cuff was used for suspension as long as they were preserved. Otherwise, artificial ligament was used. Recycled tumor-bearing bone was treated by liquid nitrogen procedure which includes frozen in liquid nitrogen for 20 min, thawed at room temperature for 15 min, and rinsed in distilled water for 15 min.

### **Data and statistical analysis**

Clinical outcome was assessed for all cases. Functional outcome was assessed by the Enneking score, including pain, function, emotional acceptance, hand positioning, manual dexterity and lifting ability, with each having a maximum of five points representing normal or full function (maximum overall score, 30 points) [8]. The patients were separated into three groups on the basis of reconstruction methods. No reconstruction group underwent tumor excision and suture of remaining soft tissue. Humeral suspension group underwent suspension of the residual humerus from the clavicle or a proximal rib with the use of biologic or artificial tendon. Prosthesis group includes total scapular prosthesis (n=9) and recycle bone and prosthesis composite (n=1). One-way ANOVA was used to compare parameters between the patient groups,

with statistical significance defined as  $p < 0.05$ .

## Results

### **Clinical outcomes**

Complications included five local recurrences, one superficial infection, one dislocation and one clavicle protrusion. The average follow-up period was 43.5 months (12 to 144 months). The average active flexion range was  $45.8^\circ$  ( $0 - 120^\circ$ ), and  $37.1^\circ$  in abduction ( $0 - 120^\circ$ ). Shoulder range of motion was severely limited in most cases. Function and hand position, which reflect shoulder ability, had low Enneking functional scores, but pain and dexterity, which reflect usefulness of hand joints, had satisfactory scores (table 2). The mean total score was 22.9 out of 30 (15 - 29), which is a satisfactory score to patients following resection of the shoulder girdle.

### **Statistical analysis**

Statistical analysis was performed on reconstruction methods to evaluate which had a significant influence on Enneking's functional score or active range of motion. There were significant differences in reconstruction methods for active range of motion (fig. 1). Prosthetic reconstruction was better score compare to other methods. The best functional score was obtained using recycled bone and prosthesis composite grafting. The total score of Enneking's functional score was not significantly different (fig. 2). The reason may be that the scoring system is established not for shoulder function only but for gross upper limb function.

In this study, the eastern Asian survey had the following features: 1. A wide variety of reconstruction methods are utilized in each institute. 2. Prostheses were used only in a single country reflecting its unavailability, 3. Bony reconstruction leads better active range of motion. 4. Recycled bone graft is commonly utilized in place of allograft due to a lack of bone bank system and has potential for better functional outcome instead of scapular prosthesis.

## Discussion

Although a previous study indicated that humeral suspension had only a limited

advantage for postoperative function, bony reconstruction provided better range of motion in this study. Even though this was true for bone defects reconstructed by either prosthesis or recycled bone, postoperative function is still lower than preoperative function. Pritsch T et al. showed that scapular prostheses, as compared with humeral suspension, had better functional results, 78.5% and 58.5% respectively, and superior cosmesis [3]. Puchner et al reported 80% in prosthesis and 58% in humeral suspension [9]. Our results were 78.6% and 71.3% which is slightly better score in humeral suspension. The ideal reconstruction would restore the excised bone and soft tissue to their preoperative condition; however, this is difficult to achieve using current medical technology, especially in the case of muscle reconstruction. If possible, some of the important muscles such as supraspinatus should be reconstructed with a latissimus dorsi flap [10] or other methods [11,12]. However, number of muscles that can be reconstructed by flap surgery is severely limited and it is impossible to reconstruct all the excised muscles surrounding scapula. Other technology such as stem cell transplantation is still under investigation in basic research [13]. Currently, our best option for reconstruction is using a prosthesis or recycled bone. Recycled bone would be perfect for bone reconstruction except for problems such as osteolytic lesions or postoperative absorption [14]. The best functional score in our cases was obtained using recycled bone and prosthesis composite grafting. That is reasonable because muscles can be reattached on grafted bone, but cannot be on the prosthesis only. Furthermore, bone reconstruction is limited to the original shape at best. Joint constraint [15] or other stable reconstruction methods are required after total scapulectomy because of the defect of some soft tissue. In fact, a reverse shoulder prosthesis is already widely used for rotator cuff tear arthropathy [16,17]. It has been shown to have superior outcomes and patient satisfaction scores compared to other reconstruction methods because it relies on the deltoid rather than an intact rotator cuff to elevate the shoulder. Even though non-tumor surgery still requires that type of improved prosthesis, tumor surgery accompanying large muscle defects requires a more sophisticated prosthesis.

One problem is that the scapula is floating in soft tissue and the prosthesis cannot be fixed in bone, resulting in postoperative instability or malposition of the prosthesis. It is not clear what shape of the scapular prosthesis is better after resection of the scapula and surrounding muscles. The scapular prosthesis could be designed to fix the clavicle or rib to reduce instability. An artificial power unit might be designed into the prosthesis to support active range of motion. Other problems with scapular prostheses are that soft tissue cannot be reattached to the prosthesis even though efforts have been made to improve the metal surface. Composite graft using recycled autograft or allograft

combined with reverse shoulder arthroplasty would provide both better stability and function.

Tsuchiya et al. reported a new recycled bone technique called frozen autografting using liquid nitrogen that can provide better bone remodeling compared to other heat treated autografting [18,19]. When the tumor lesion is not osteolytic, frozen recycled scapular autograft could be an option for reconstruction. Even better function is expected when the recycled bone is combined with a reverse shoulder prosthesis.

## Conclusion

There was a variety of reconstruction methods after scapulectomy in the eastern Asian countries. Although better functional scores was obtained using scapular prosthesis or recycled bone and prosthesis composite grafting, postoperative function is still lower than preoperative function. Modified designed prosthesis with or without combination of recycle bone or allograft would restore the lost shoulder function in the future.

## Conflict of interest statement

The authors declare that they have no competing interest.

## References

- [1] K.S. Kaa, P.H. Jørgensen, J.O. Søjbjerg, H. V Johannsen, Reverse shoulder replacement after resection of the proximal humerus for bone tumours., *Bone Joint J.* 95-B (2013) 1551–5.
- [2] R. Capanna, F. Totti, I.C.M. Van der Geest, D.A. Müller, Scapular allograft reconstruction after total scapulectomy: surgical technique and functional results., *J. Shoulder Elbow Surg.* 24 (2015) e203–11.
- [3] T. Pritsch, J. Bickels, C.C. Wu, M.H. Squires, M.M. Malawer, Is scapular endoprosthesis functionally superior to humeral suspension?, *Clin. Orthop. Relat. Res.* 456 (2007) 188–95. doi:10.1097/01.blo.0000238840.26423.b6.
- [4] J.H. Schwab, E.A. Athanasian, C.D. Morris, P.J. Boland, J.H. Healey, Function correlates with deltoid preservation in patients having scapular replacement., *Clin. Orthop. Relat. Res.* 452 (2006) 225–30. doi:10.1097/01.blo.0000229323.37793.6d.



- [5] B.C. Vrettos, W.A. Wallace, L. Neumann, S.P. Frostick, Total scapular replacement: medium-term follow-up., *J. Shoulder Elbow Surg.* 13 (2004) 472–5.
- [6] J.C. Wittig, J. Bickels, F. Wodajo, K.L. Kellar-Graney, M.M. Malawar, Constrained total scapula reconstruction after resection of a high-grade sarcoma., *Clin. Orthop. Relat. Res.* (2002) 143–55.
- [7] S.M. Levin, The scapula is a sesamoid bone., *J. Biomech.* 38 (2005) 1733–4; author reply 1734–6.
- [8] W.F. Enneking, W. Dunham, M.C. Gebhardt, M. Malawar, D.J. Pritchard, A system for the functional evaluation of reconstructive procedures after surgical treatment of tumors of the musculoskeletal system., *Clin. Orthop. Relat. Res.* (1993) 241–246.
- [9] S.E. Puchner, J. Panotopoulos, R. Puchner, R. Schuh, R. Windhager, P.T. Funovics. Primary malignant tumours of the scapula—a review of 29 cases., *Int. Orthop.* 38 (2014) 2155–62.
- [10] T. Shimizu, A. Kido, K. Honoki, K. Murata, H. Fujii, B. Higuchi, T. Ishihara, Y. Takeshita, M. Shima, H. Yajima, M. Akahane, Y. Tanaka, A successful reconstruction using a frozen autograft and a pedicled latissimus dorsi flap after a S12345B shoulder girdle resection in a patient with osteosarcoma., *J. Reconstr. Microsurg.* 28 (2012) 155–9.
- [11] C.L. Gibbons, R.S. Bell, J.S. Wunder, A.M. Griffin, B. O’Sullivan, C.N. Catton, A.M. Davis, Function after subtotal scapulectomy for neoplasm of bone and soft tissue., *J. Bone Joint Surg. Br.* 80 (1998) 38–42.
- [12] F. Lichtenegger, D. Ulrich, M. Weber, E.-M. Noah, N. Pallua, [Radical scapulectomy with trapezius flap in soft tissue sarcoma of the shoulder girdle]., *Der Chir. Zeitschrift Für Alle Gebiete Der Oper. Medizin.* 74 (2003) 1074–7.
- [13] J.H. Oh, S.W. Chung, S.H. Kim, J.Y. Chung, J.Y. Kim, 2013 Neer Award: Effect of the adipose-derived stem cell for the improvement of fatty degeneration and rotator cuff healing in rabbit model., *J. Shoulder Elbow Surg.* 23 (2014) 445–55.
- [14] H. Koyanagi, S. Matsumoto, T. Shimoji, T. Tanizawa, K. Ae, K. Shinomiya, A. Okawa, N. Kawaguchi, Long-term results from use of pasteurized bone., *J. Orthop. Sci.* 17 (2012) 605–13.
- [15] M. Post, Constrained arthroplasty of the shoulder., *Orthop. Clin. North Am.* 18 (1987) 455–62.
- [16] L. De Wilde, P. Boileau, H. Van Der Bracht, Does reverse shoulder arthroplasty for tumors of the proximal humerus reduce impairment?, *Clin. Orthop. Relat. Res.* 469 (2011) 2489–2495.

- [17] N. Bonneville, P. Mansat, J. Lebon, J.-M. Laffosse, P. Bonneville, Reverse shoulder arthroplasty for malignant tumors of proximal humerus, *J. Shoulder Elb. Surg.* 24 (2015) 36–44.
- [18] H. Tsuchiya, S.L. Wan, K. Sakayama, N. Yamamoto, H. Nishida, K. Tomita, Reconstruction using an autograft containing tumour treated by liquid nitrogen., *J. Bone Joint Surg. Br.* 87 (2005) 218–225.
- [19] Y. Tanzawa, H. Tsuchiya, T. Shirai, K. Hayashi, Z. Yo, K. Tomita, Histological examination of frozen autograft treated by liquid nitrogen removed after implantation, *J. Orthop. Sci.* 14 (2009) 761–768.

## Figure Legends

### Figure 1

Comparison between surgeries involving no reconstruction, humeral suspension (soft tissue reconstruction only) or prosthetic reconstruction (including composite grafting). There were significant differences of postoperative active range of motion in each group.

### Figure 2

The total score of Enneking's functional score was not significantly different (figure 2). The reason may be that the scoring system is established not for shoulder function only but for gross upper limb function.

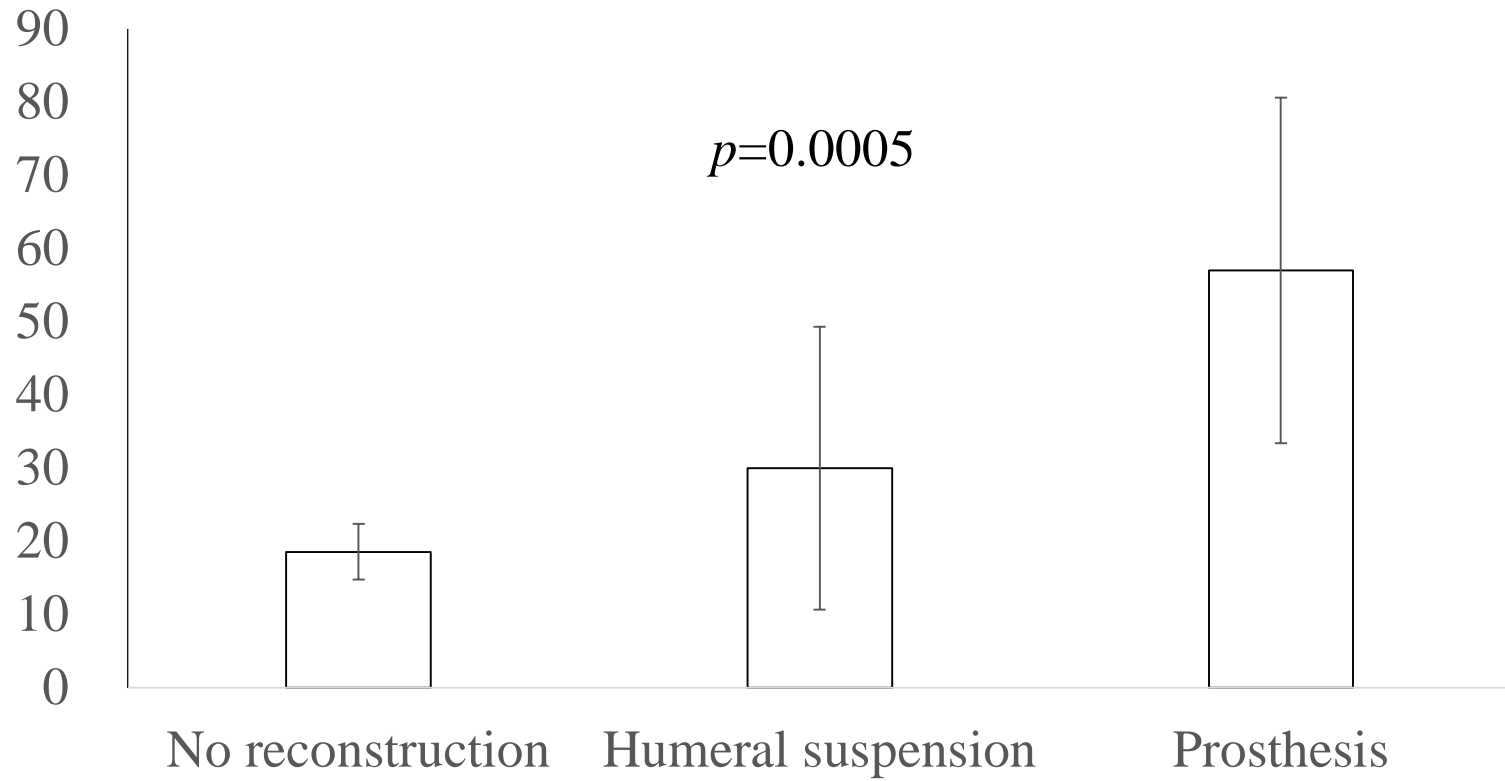
Table 1 Patient characteristics, surgical procedures, complications and postoperative oncological outcomes

CDF, continuous disease free; NED, no evidence of disease; AWD, alive with disease; DOD, died of disease; M, male; F, female.

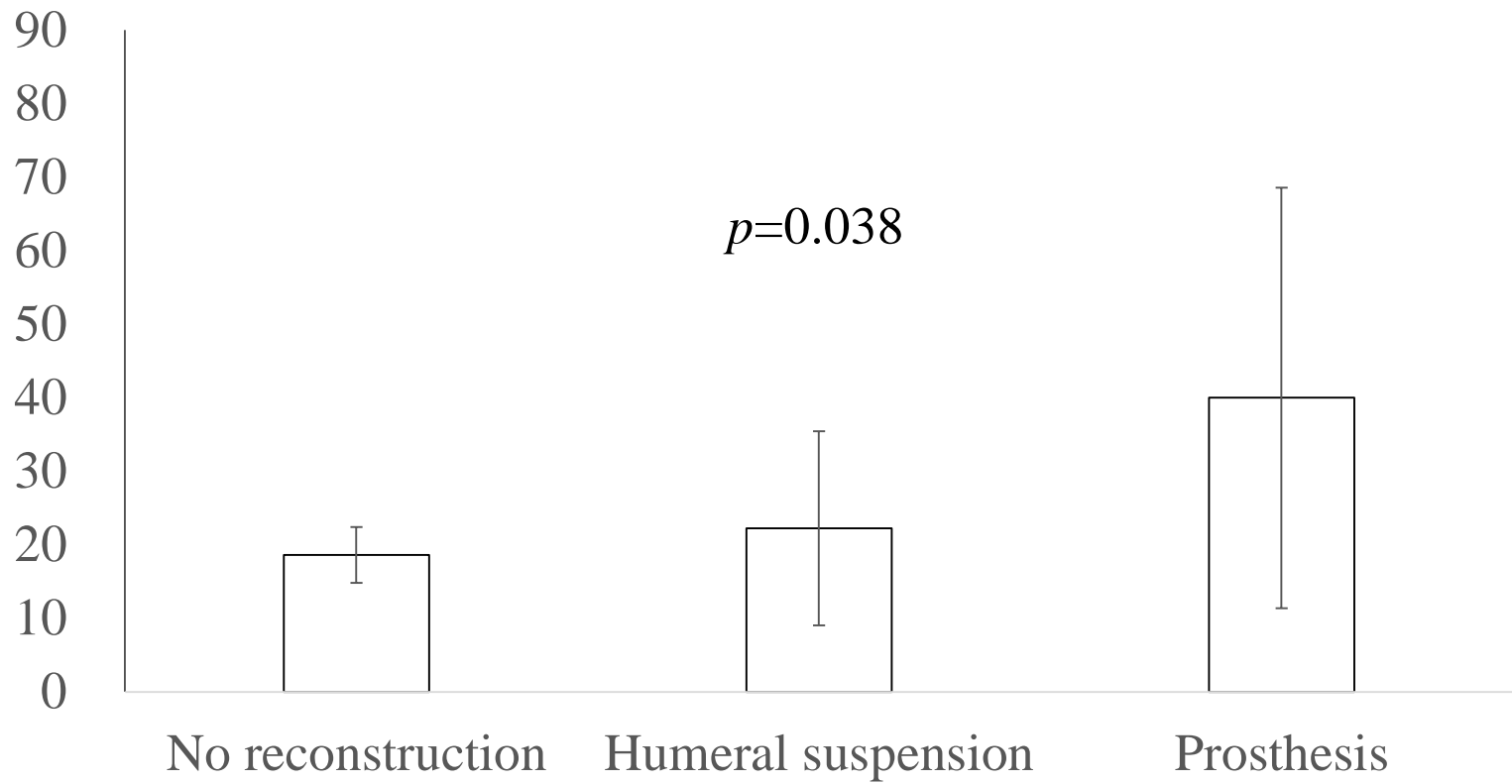
Table 2 Functional score and active range of motion of shoulder joint.

Functional outcome was assessed by the Enneking score, including pain, function, emotional acceptance, hand positioning, manual dexterity and lifting ability, with each having a maximum of five points representing normal or full function (maximum overall score, 30 points).

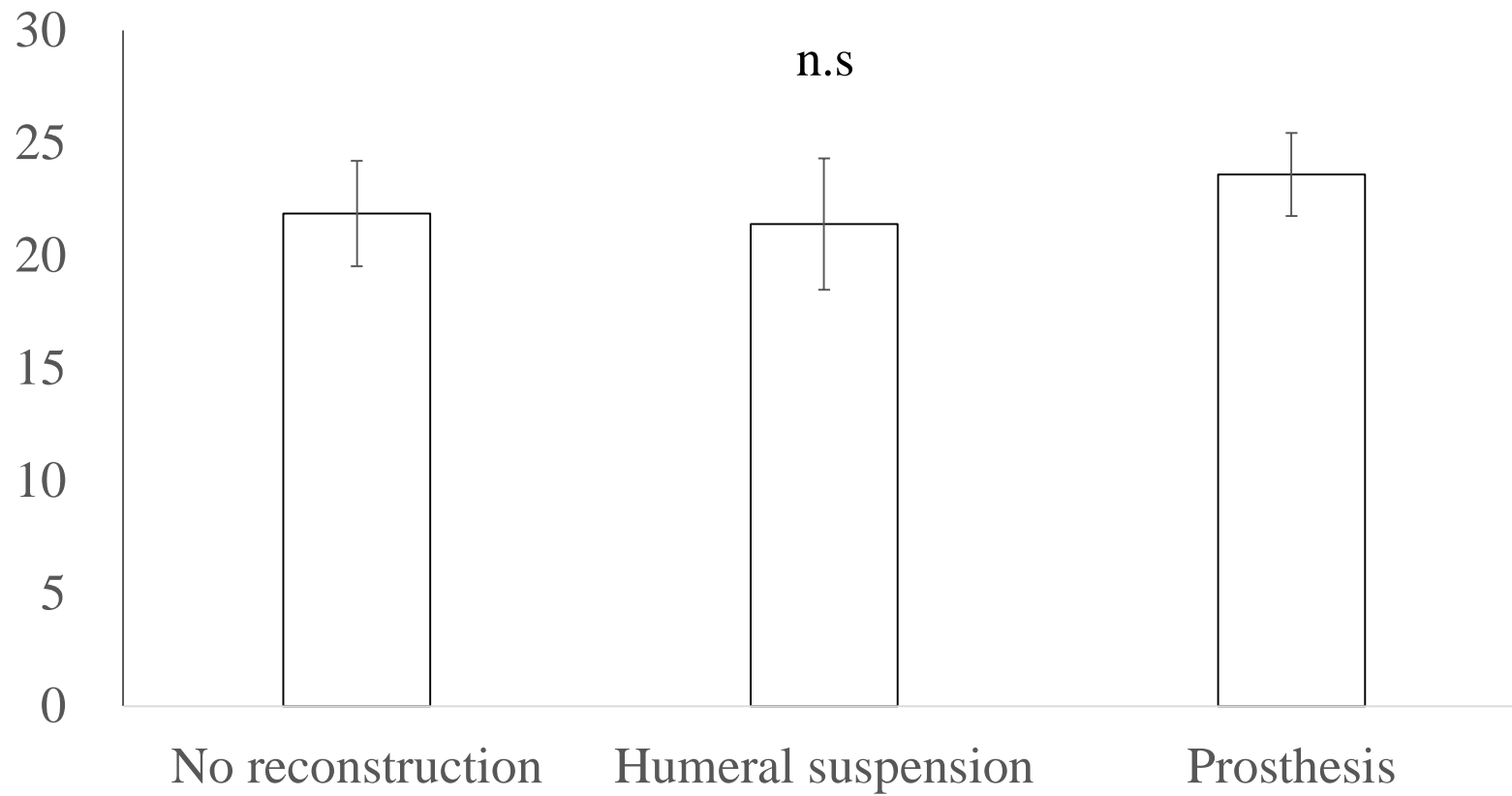
## Flexion



## Abduction



## Functional score



<b>N</b>		33
<b>Gender</b>	Male	17
	Female	16
<b>Age</b>		43.1(15-75)
<b>Diagnosis</b>	Chondrosarcoma	16
	Ewing's sarcoma	6
	Osteosarcoma	3
	Metastasis	2
	Synovial sarcoma	2
	Fibrosarcoma	1
	Liposarcoma	1
	Malignant fibrous histiocyoma	1
	Angiosarcoma	1
<b>Surgical stage (Enneking)</b>	IB	3
	IIA	1
	IIB	24
	IIIB	1
<b>Chemotherapy</b>	Yes	13
	No	20
<b>Radiation</b>	No	33
<b>Reconstruction</b>	No reconstruction	8
	Soft tissue (humeral suspension)	15
	Bone (prosthesis)	10
<b>Complication</b>	Local recurrence	5
	Superficial infection	1
	Dislocation	1
	Clavicle protrusion	1
<b>Follow up (M)</b>		43.4
<b>Oncological outcome</b>	CDF	11
	NED	15
	AWD	4
	DOD	3

		No reconstruction	Humeral suspension	Prosthesis	All
Functional score (ISOLS)	Pain	4.8	4.6	5.0	4.8
	Function	2.5	3.3	3.6	3.4
	Emotional acceptance	3.8	4.4	4.9	4.4
	Hand positioning	2.5	1.3	1.9	2.2
	Dexterity	4.8	4.9	5.0	4.9
	Lifting ability	3.0	2.9	3.3	3.2
	Total	21.3	21.4	23.6	22.9
		%	70.8	71.3	78.6
Range of motion	active flexion	17.5	30.0	57.0	45.8
	active abduction	17.5	22.3	40.0	37.1