Successful treatment with recombinant thrombomodulin for B-cell lymphoma-associated hemophagocytic syndrome complicated by disseminated intravascular coagulation

メタデータ	言語: English 出版者: 公開日: 2021-06-28 キーワード (Ja): キーワード (En): 作成者: Uni, Masahiro, Yoshimi, Akihide, Maki, Hiroaki, Maeda, Daichi, Nakazaki, Kumi, Nakamura, Fumihiko, Fukayama, Masashi, Kurokawa, Mineo, 前田, 大地 メールアドレス: 所属:
URL	https://doi.org/10.24517/00062691

This work is licensed under a Creative Commons Attribution-NonCommercial-ShareAlike 3.0 International License.

Int J Clin Exp Pathol 2013;6(6):1190-1194
www.ijcep.com /ISSN:1936-2625/IJCEP1304009

Case Report

Successful treatment with recombinant thrombomodulin for B-cell lymphoma-associated hemophagocytic syndrome complicated by disseminated intravascular coagulation

Masahiro Uni[1], Akihide Yoshimi[1,2], Hiroaki Maki[1], Daichi Maeda[3], Kumi Nakazaki[1], Fumihiko Nakamura[1], Masashi Fukayama[3], Mineo Kurokawa[1,2]

[1]Department of Hematology & Oncology, Graduate School of Medicine, The University of Tokyo, Tokyo, Japan; [2]Department of Cell Therapy & Transplantation Medicine, The University of Tokyo Hospital, Tokyo, Japan; [3]Department of Pathology, Graduate School of Medicine, The University of Tokyo, Tokyo, Japan

Received April 6, 2013; Accepted May 1, 2013; Epub May 15, 2013; Published June 1, 2013

Abstract: We report here a 47-year-old male with the diagnosis of high-grade B-cell lymphoma and hemophagocytosis accompanying disseminated intravascular coagulation (DIC). Lymphoma-associated hemophagocytic syndrome (LAHS) is a life-threatening disorder, and LAHS secondary to B-cell lymphoma is relatively rare compared to that secondary to T- or NK/T-cell lymphoma in Western countries. T- or NK/T-cell LAHS is sometimes combined with DIC, which makes patients' outcomes even worse, but few reports of B-cell LAHS accompanying DIC has been published so far. We successfully treated a patient with this condition with recombinant thrombomodulin (rTM), a novel agent for DIC. We believe that rTM is a therapeutic option in cases with B-cell LAHS accompanying DIC.

Keywords: B-cell lymphoma, lymphoma-associated hemophagocytic syndrome, disseminated intravascular coagulation, recombinant thrombomodulin

Introduction

Hemophagocytic syndrome (HPS) is usually acquired after infection, lymphoma and autoimmune diseases [1]. Patients with intravascular lymphoma are sometimes accompanied by lymphoma-associated HPS (LAHS) [2]. Since patients with lymphoma-associated HPS (LAHS) are thought to have worse prognosis than those without, prompt diagnosis and treatment are necessary [3-6]. Treatment strategy for LAHS is to start combination chemotherapy as soon as possible, and rituximab and CHOP (cyclophosphamide, doxorubicin, vincristine and prednisolone) (R-CHOP) regimen is often used for B-cell LAHS [3-5, 7-9]. Although supportive care is also important, it has not been discussed enough so far. Disseminated intravascular coagulation (DIC) is sometimes accompanied by T- or NK/T-cell LAHS and predicts a lower survival rate. On the other hand, DIC with B-cell LAHS is relatively rare and its treatment strategy has not been established yet [2, 7].

Recombinant thrombomodulin (rTM) has emerged as a new treatment option for DIC, which inhibits the action of activated Factor V and VIII by activating protein C [10, 11]. The efficacy of rTM is excellent in improvement of sepsis-related DIC and reduction of bleeding events [11].

Herein we report the first case of successful treatment with rTM for B-cell LAHS accompanying DIC without invasion of tumor cells into blood vessels or Epstein-Barr virus (EBV) infection.

Case report

A 47-year-old male suffering from multiple sclerosis (MS) was admitted to our institution due to fever and weight loss. Physical examination revealed no evidence of lymphadenopathy. His

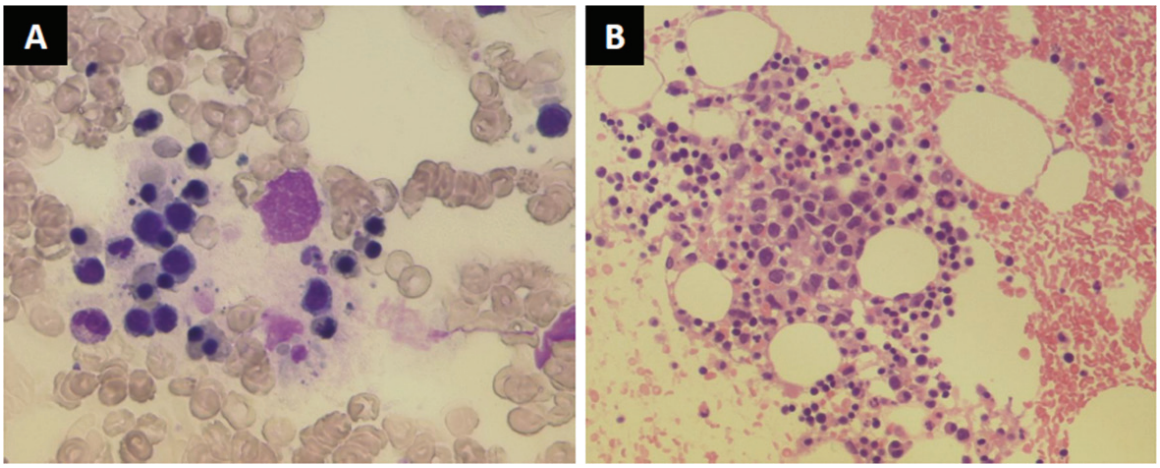

Figure 1. Hematoxylin-eosin stain of bone marrow aspiration showing increased phagocytic cells (A). Hematoxylin-eosin stain of bone marrow biopsy shows invasion and nodular proliferation of atypical lymphocytes with large, cleaved and constricted nuclei (B).

leukocyte count was 6.7 × 10^9 /L with 3% lymphoid cells, hemoglobin 94 g/L and platelet count 65 × 10^9 /L. Serum biochemistry revealed lactate dehydrogenase 786 U/L, aspartate transaminase 66 U/L, alanine transaminase 116 U/L, alkaline phosphatase 1,337 U/L and soluble interleukin-2 receptor (sIL-2R) 18,261 U/mL. Progression of MS was unlikely because brain magnetic resonance imaging did not disclose novel lesions. Computed tomography (CT) scan showed hepatosplenomegaly. F18-fluprodeoxyglucose-positron emission tomography (FDG-PET) exhibited increased uptakes in the spleen and extensive bones. Bone marrow biopsy was notable for diffuse proliferation of large to medium-sized lymphoid cells with constricted nuclei that were positively stained for CD20 on immunohistochemistry. Flow cytometric analysis of the bone marrow specimen demonstrated that the neoplastic cells were positive for CD19 and negative for CD5, CD10 and CD30. EBV encoded RNA-1 in situ hybridization resulted in negative study. Monoclonal rearrangement of immunoglobulin heavy chain gene was demonstrated by polymerase chain reaction amplification. Cytogenetic study revealed near-tetraploidy with chromosomal abnormalities including 3q21 and 19q13. We suspected Asian variant intravascular lymphoma (AIVL) for this high-grade B-cell lymphoma as it has been reported that AIVL is frequently associated with HPS [2]. However, random skin biopsy did not show invasion of tumor cells into blood vessels. We therefore made the diagnosis of high-grade B-cell lymphoma, most likely diffuse large B-cell lymphoma.

He began to complain of right upper quadrant pain. Pancytopenia progressed with leukocyte count of 1.8 × 10^9 /L, hemoglobin level 73 g/L and platelet count 42 × 10^9 /L. Other findings included plasma fibrinogen level of 1.26 g/L and serum ferritin of 24,387 mg/L. Hemophagocytic histiocytes were observed in the reexamined bone marrow (**Figure 1**). Although no definitive diagnostic criteria exist for LAHS, we diagnosed the patient as having B-cell LAHS, based on the manifestation of fever, splenomegaly, cytopenia, hypofibrinogenemia, hemophagocytosis in the bone marrow, hyperferritinemia and elevated sIL-2R. Fibrinogen degradation products (FDP) level and prothrombin time were 86.8 mg/L and 84%, respectively. These data satisfied the criteria of overt DIC of the scoring system for DIC of International Society on Thrombosis and Hemostasis (ISTM). Treatment of DIC was initiated with rTM at a daily dose of 380 U/kg for six consecutive days. Etoposide was added to regular CHOP regimen and these treatments led to transient exacerbation but eventual improvement of lymphoma, DIC, and pancytopenia (**Figure 2**).

Rituximab and CHOP (R-CHOP) regimen was performed for five additional courses with vincristine excluded for the last three courses because of severe peripheral neuropathy. He achieved complete remission after 6 courses

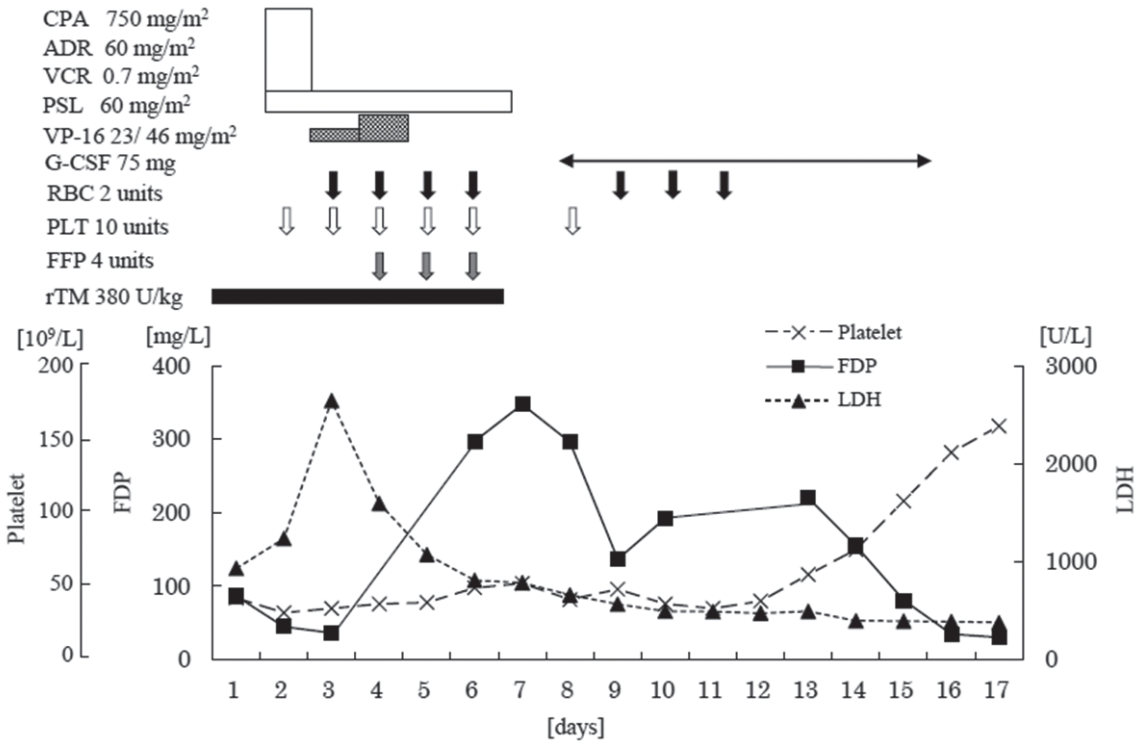

Figure 2. A clinical course and laboratory data of the present case. Abbreviations and symbols: CPA, cyclophosphamide; ADR, doxorubicin; VCR, vincristine; PSL, prednisolone; VP-16, etoposide; G-CSF, filgrastim. A double-headed arrow means a subcutaneous shot of 75 mg/day of filgrastim for six days. RBC, red blood cells. Each black arrow means transfusion of 2 units (corresponding to one unit in western countries) of red blood cells.; PLT, platelet. Each white arrow means transfusion of 10 units of platelets. FFP, fresh frozen plasma. Each gray arrow means transfusion of 4 units of FFP. rTM, recombinant thrombomodulin; FDP, fibrinogen degradation products; LDH, lactate dehydrogenase.

of combination chemotherapy. CT imaging showed disappearance of hepatosplenomegaly. Cytopenias and hypofibrinogenemia ameliorated. Levels of sIL-2R and ferritin were markedly reduced to 477 U/ml and 1,734 mg/L, respectively.

Discussion

LAHS secondary to B-cell lymphoma is unusual, and B-cell LAHS accompanying DIC is rare [1, 7, 12, 13]. In recent years, there have been increasing number of reports that B-cell LAHS is recurrent in AIVL and that DIC accompanies a subset of AIVL with B-cell LAHS [2, 7].

Standard treatment strategies for HPS consist of immunosuppressants and supportive therapy. In case of LAHS, combination chemotherapy should be added immediately, since it develops rapidly and becomes fatal in most patients. For B-cell LAHS, R-CHOP regimen is generally used, and stem cell transplantation might be considered for relapsed cases [3-5, 7-9]. Etoposide was administered in addition to the standard CHOP regimen of DLBCL in this case, because this medication was already shown to be effective for EBV-related HPS [3, 14, 15], and the remedy led complete response of lymphoma and resolution of HPS.

On the other hand, as for the supportive therapy, few pieces of evidence have been established, and here we applied rTM for the management of DIC in B-cell LAHS. Thrombomodulin forms a complex with thrombin, and this complex activates protein C approximately 1,000 times faster than thrombin alone. Activated protein C acts as an endogenous anticoagulant factor by dissolving Factor Va and VIIIa. Recombinant TM is an emerging treatment option for DIC, composed of the active, extracellular domain of thrombomodulin. Efficacy and safety of rTM for sepsis-induced DIC have

already been demonstrated [10, 11]. We successfully managed DIC in B-cell LAHS with rTM, indicating that the reagent may be also effective in this setting.

This patient presented with splenomegaly and FDG-PET exhibited increased uptakes in the spleen. No reports have ever pointed out whether clinicians should regard splenomegaly as a feature of lymphoma and/or HPS in such cases, or no definitive criteria has been established for B-cell lymphomas with HPS. In this case, we diagnosed B-cell lymphoma on histopathological findings and regarded splenomegaly as one of the diagnostic criteria for HPS. Murase et al. proposed a diagnostic criteria for B-cell LAHS in the previous study [2], and our case fulfills it: (a) hemophagocytosis in the hemopoietic system, (b) hepatomegaly and/or splenomegaly, (c) bone marrow invasion of the lymphoma cells, (d) a lack of overt lymphadenopathy and tumor formation, at least three of these four conditions. According to this report, two thirds of B-cell LAHS have definitely been histopathologically classified as IVL, and rest of them were also diagnosed as IVL by autopsy. In our case, however, random skin biopsy and bone marrow biopsy did not show evidence of IVL, despite the features reminiscent of AIVL such as fever, splenomegaly, cytopenia, hypofibrinogenemia, hemophagocytosis in the bone marrow, hyperferritinemia and elevated sIL-2R. Hence, we may need to reexamine whether AIVL would really account for almost all cases of B-cell lymphoma with features of HPS. In this setting, evaluation of the splenomegaly by FDG uptakes and active histological surveys may be useful to determine whether it is induced by LAHS and/or AIVL.

In conclusion, R-CHOP therapy combined with etoposide and rTM is a promising approach for unfavorable B-cell LAHS accompanying DIC.

Statement of conflict of interest

The authors have no potential conflicts of interest.

Address correspondence to: Dr. Mineo Kurokawa, Department of Hematology and Oncology, the Graduate School of Medicine, the University of Tokyo, 7-3-1 Hongo, Bunkyo-ku, Hongo 113-8655, Japan. Tel: +81-3-5800-9092; Fax: +81-3-5840-8677; E-mail: kurokawa-tky@umin.ac.jp

References

[1] Florena AM, Iannitto E, Quintini G, Franco V. Bone marrow biopsy in hemophagocytic syndrome. Virchows Arch 2002; 441: 335-44.

[2] Murase T, Nakamura S, Kawauchi K, Matsuzaki H, Sakai C, Inaba T, Nasu K, Tashiro K, Suchi T, Saito H. An Asian variant of intravascular large B-cell lymphoma: clinical, pathological and cytogenetic approaches to diffuse large B-cell lymphoma associated with haemophagocytic syndrome. Br J Haematol 2000; 111: 826-34.

[3] Ishii E, Ohga S, Imashuku S, Yasukawa M, Tsuda H, Miura I, Yamamoto K, Horiuchi H, Takada K, Ohshima K, Nakamura S, Kinukawa N, Oshimi K, Kawa K. Nationwide survey of hemophagocytic lymphohistiocytosis in Japan. Int J Hematol 2007; 86: 58-65.

[4] Miyahara M, Sano M, Shibata K, Matsuzaki M, Ibaraki K, Shimamoto Y, Tokunaga O. B-cell lymphoma-associated hemophagocytic syndrome: clinicopathological characteristics. Ann Hematol 2000; 79: 378-88.

[5] Takahashi N, Chubachi A, Kume M, Hatano Y, Komatsuda A, Kawabata Y, Yanagiya N, Ichikawa Y, Miura AB, Miura I. A clinical analysis of 52 adult patients with hemophagocytic syndrome: the prognostic significance of the underlying diseases. Int J Hematol 2001; 74: 209-13.

[6] Tong H, Ren Y, Liu H, Xiao F, Mai W, Meng H, Qian W, Huang J, Mao L, Tong Y, Wang L, Qian J, Jin J. Clinical characteristics of T-cell lymphoma associated with hemophagocytic syndrome: comparison of T-cell lymphoma with and without hemophagocytic syndrome. Leuk Lymphoma 2008; 49: 81-7.

[7] Han AR, Lee HR, Park BB, Hwang IG, Park S, Lee SC, Kim K, Lim HY, Ko YH, Kim SH, Kim WS. Lymphoma-associated hemophagocytic syndrome: clinical features and treatment outcome. Ann Hematol 2007; 86: 493-8.

[8] Shimazaki C, Inaba T, Nakagawa M. B-cell lymphoma-associated hemophagocytic syndrome. Leuk Lymphoma 2000; 38: 121-30.

[9] Yeh YM, Chang KC, Chen YP, Kao LY, Tsai HP, Ho CL, Wang JR, Jones D, Chen TY. Large B cell lymphoma presenting initially in bone marrow, liver and spleen: an aggressive entity associated frequently with haemophagocytic syndrome. Histopathology 2010; 57: 785-95.

[10] Moll S, Lindley C, Pescatore S, Morrison D, Tsuruta K, Mohri M, Serada M, Sata M, Shimizu H, Yamada K, White GC 2nd. Phase I study of a novel recombinant human soluble thrombomodulin, ART-123. J Thromb Haemost 2004; 2: 1745-51.

[11] Saito H, Maruyama I, Shimazaki S, Yamamoto Y, Aikawa N, Ohno R, Hirayama A, Matsuda T,

Asakura H, Nakashima M, Aoki N. Efficacy and safety of recombinant human soluble thrombomodulin (ART-123) in disseminated intravascular coagulation: results of a phase III, randomized, double-blind clinical trial. J Thromb Haemost 2007; 5: 31-41.

[12] Falini B, Pileri S, De Solas I, Martelli MF, Mason DY, Delsol G, Gatter KC, Fagioli M. Peripheral T-cell lymphoma associated with hemophagocytic syndrome. Blood 1990; 75: 434-44.

[13] Wilson MS, Weiss LM, Gatter KC, Mason DY, Dorfman RF, Warnke RA. Malignant histiocytosis. A reassessment of cases previously reported in 1975 based on paraffin section immunophenotyping studies. Cancer 1990; 66: 530-6.

[14] Imashuku S, Hibi S, Tabata Y, Todo S. Hemophagocytic syndrome in five patients with Epstein-Barr virus negative B-cell lymphoma. Cancer 1999; 85: 2298-300.

[15] Imashuku S, Kuriyama K, Teramura T, Ishii E, Kinugawa N, Kato M, Sako M, Hibi S. Requirement for etoposide in the treatment of Epstein-Barr virus-associated hemophagocytic lymphohistiocytosis. J Clin Oncol 2001; 19: 2665-73.